

# Bone-Tendon-Autograft Anterior Cruciate Ligament Reconstruction: A New Anterior Cruciate Ligament Graft Option



CPT. Steven R. Wilding, M.D., CPT. Christian A. Cruz, M.D., LCDR. Brian J. Mannino, M.D., CPT. James B. Deal, M.D., CPT Jeffrey Wake, D.O., A.T.C., and Craig R. Bottoni, M.D.

**Abstract:** The bone-tendon-bone (BTB) autograft is widely used for anterior cruciate ligament (ACL) reconstruction. However, the primary disadvantages of this technique include postoperative kneeling pain, the risk of perioperative patellar fracture, and graft-tunnel mismatch. Therefore, a single bone plug technique for ACL reconstructions was developed to mitigate the disadvantages of the BTB technique. To differentiate this graft, we have coined the term BTA, for bone-tendon-autograft. The middle third of the patellar tendon is used with a typical width of 10 to 11 mm. A standard tibial tubercle bone plug is harvested. The length of the patellar tendon and graft construct is then measured. If the tendon is >45 mm and the construct at least 70 mm, then we proceed with the BTA technique. At the inferior pole of the patella, electrocautery is used to harvest the tendon from the patella. The advantages of this technique include faster graft harvest and preparation. Obviating the patellar bone plug harvest should eliminate the risk of perioperative patellar fracture and theoretically will mitigate donor site morbidity and kneeling pain, 2 of the most commonly cited complications of the use of BTB autografts for ACL reconstruction. In conclusion, the BTA technique is a reliable technique for ACL reconstruction.

In 1963, Kenneth G. Jones published his experience with the use of the central one-third of patellar tendon autograft. With a slight variation in the technique, the use of the bone-patellar tendon-bone autograft for anterior cruciate ligament (ACL) reconstruction became the most commonly used technique and is considered by most surgeons as the “gold standard.”<sup>1</sup> The primary disadvantages of this technique are donor site morbidity, specifically postoperative kneeling pain and the risk of perioperative patellar fracture, ostensibly from the harvest of the patellar bone.<sup>2-5</sup> Additionally,

anatomical variability in patellar tendon length can result in graft-tunnel mismatch, complicating tibial fixation and potentially precluding successful reconstruction.<sup>6</sup>

Anterior knee pain, specifically with kneeling, has been reported to occur in 17% of patients after patellar tendon ACL reconstruction.<sup>2,3,5</sup> This can result in significant morbidity for active duty military members who require frequent kneeling to perform their duties. The infrequent complication of a patellar fracture following ACL reconstruction usually requires additional surgery and typically results in less optimal results.<sup>4</sup> Graft-tunnel mismatch occurs when a long patellar tendon necessitates changes in the surgical technique because of the bone plug extruding from the tibial tunnel.<sup>6</sup> The risk of this complication has increased with transition to femoral independent tunnel creation techniques. The transtibial ACL reconstruction technique resulted in a vertical graft because of a more anteriorly placed femoral tunnel. The consequence of this technique was a greater intra-articular distance and less likelihood of graft-tunnel mismatch. The evolution of independent femoral tunnel drilling has resulted in a tunnel placement further posterior on the femoral condyle that more closely approximates the footprint of the posterolateral bundle. This change results in decreased intra-articular distance

*From the Tripler Army Medical Center, Department of Orthopaedic Surgery, Honolulu Hawaii, U.S.A.*

*The authors report that they have no conflicts of interest in the authorship and publication of this article. Full ICMJE author disclosure forms are available for this article online, as [supplementary material](#). The views expressed in this abstract/manuscript are those of the authors and do not reflect the official policy or position of the Department of the Army, Department of Defense, or the US Government.*

*Received April 12, 2020; accepted June 7, 2020.*

*Address correspondence to Christian Cruz, M.D., 1 Jarrett White Rd., Honolulu, HI 96859, U.S.A. E-mail: [chcruz93@gmail.com](mailto:chcruz93@gmail.com)*

*© 2020 by the Arthroscopy Association of North America. Published by Elsevier. This is an open access article under the CC BY-NC-ND license (<http://creativecommons.org/licenses/by-nc-nd/4.0/>).*

*2212-6287/20659*

*<https://doi.org/10.1016/j.eats.2020.06.021>*

for the graft to traverse and, consequently, a greater risk of graft-tunnel mismatch.<sup>6</sup>

To eliminate graft-tunnel mismatch using patellar tendon autograft, the senior author at our institution has begun using a single bone plug technique, when feasible, for ACL reconstructions over the past 4 years. To differentiate this graft from the well-recognized acronym, BTB or bone-tendon-bone, we have coined the term BTA, for bone tendon autograft, to differentiate this graft from the more commonly used autograft.

### Preoperative Evaluation

When a patient presents to our clinic with an ACL tear and desires operative management, we provide the patient with a detailed explanation of all options for his or her graft choice. We also provide a handout we designed that explains the risks and benefits of each graft choice based on currently accepted literature. We believe it is important for the patient to have input into the graft choice, and therefore give him or her the resources to make an informed decision. If the patient chooses a bone-patellar tendon-bone autograft, we then ascertain whether the knee, and specifically the patellar tendon length is suitable for the BTA technique. Patellar tendon length is first measured on T2 sagittal magnetic resonance imaging (MRI) scans and subsequently confirmed intraoperatively. The minimum patellar tendon length we have determined that allows use of this technique is 45 mm. This assumes a 30- to 35-mm intra-articular (femoral to tibial apertures) and 20- to 25-mm tibial bone plug (which is inserted into the femur). Thus, a minimum of 15 to 20 mm of the graft remains for tibial fixation. Based on our experience, an MRI scan showing a patellar tendon length of 45 mm typically correlates with a total construct length of greater than 70 mm. The fixation in the femur is performed with a commercially available biocomposite or metal interference screw. For the tibial fixation, a bioabsorbable interference screw (RetroScrew, Arthrex, Naples, FL) is used. This technique is unique in that the screw is first passed into the joint over a suture and then inserted into the tibial tunnel from proximal to distal with a cannulated driver inserted up the tibial tunnel. The advantage of the RetroScrew is that it is inserted into the strong subchondral bone of the proximal tibia, thus resulting in better fixation strength. Additionally, unlike conventional tibial interference screws, the insertion of the RetroScrew is in line with the insertion of the tendon. For added fixation, the sutures are secured to a suture anchor (4.75 mm SwiveLock, Arthrex) in the proximal tibia just distal to the tibial tunnel aperture. Alternatively, if the tendon is exceptionally long (>55 mm), a standard retrograde interference screw may be utilized.

## Technique

### Harvest

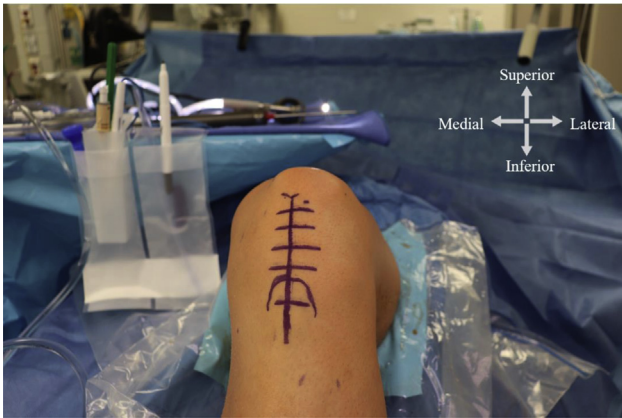
After a diagnostic arthroscopy and any meniscal or chondral pathology are addressed, the patellar tendon graft is harvested. A midline incision is made from the inferior pole of the patella to the superior aspect of the tibial tubercle and dissection is made down to the level of the paratenon (Fig 1). The paratenon is split and carefully reflected off of the underlying tendon, thus allowing side-to-side repair after reconstruction of the ACL (Fig 2).

The middle third of the patellar tendon is used with a typical width of 10 to 11 mm. A full-thickness longitudinal incision of the patellar tendon is made from the inferior pole of the patella to the tibial tubercle. At the tibial tubercle, 20 to 25 mm of bone is measured and marked with electrocautery for the bone plug. An ACL saw blade is used to harvest the bone plug in a trapezoidal shape. The bone plug and tendon are then lifted off until the only remaining attachment is to the patella. The length of the patellar tendon and graft construct is now measured. If the tendon is >45 mm and the construct at least 70 mm, then we proceed with the BTA technique. At the inferior pole of the patella, electrocautery is used to harvest the tendon from the patella (Fig 3). Typically, an additional 5 to 10 mm of tendon can be obtained from the inferior pole. If, however, the construct is shorter than 70 mm, then the patellar bone plug is harvested and the standard BTB technique is used.

### Graft Preparation

The initial graft preparation is the same as is used for a BTB graft. Initial graft preparation involves removing any adherent fat pad off of the deep side of the patellar tendon portion of the graft. This can be completed with scissors or a rongeur. A rongeur is then used to decrease the circumference of the bone plug to 9 mm. Once the bone plug is contoured to the appropriate size, a 2.0-mm drill is used to create 2 holes through the cortical portion of the tibial bone plug. A No. 2 FiberWire is then passed through each of the drill holes (FiberWire, Arthrex).

The tendinous end of the BTA graft is prepared similar to a hamstring or other soft-tissue ACL graft. A locking No. 2 FiberWire looped suture is passed through the tendon (FiberLoop, Arthrex). The circumference of the tibial side of the graft is also measured to ensure appropriate tibial tunnel diameter while allowing sufficient space for bone plug passage. The cancellous portion of the bone plug is colored purple with a sterile marking pen, and the graft is placed on 15 to 20 pounds of tension until insertion (Fig 4).

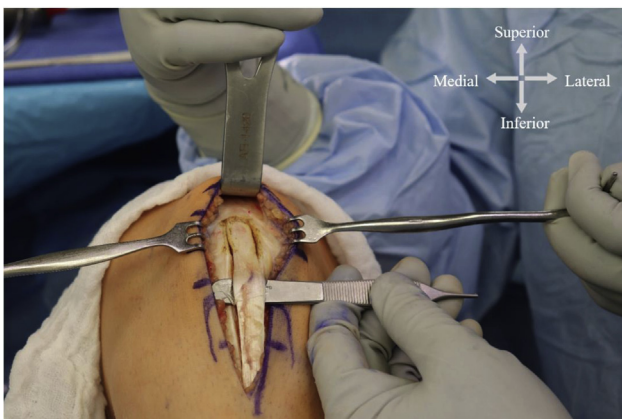


**Fig 1.** With the patient positioned supine, the knee is flexed to 90°. A midline incision is used from the inferior pole of the patella to the superior aspect of the tibial tubercle. The medial aspect of the knee is located on the left of the figure, with the lateral knee of the right of the figure. The head of the patient is at the top of the figure.

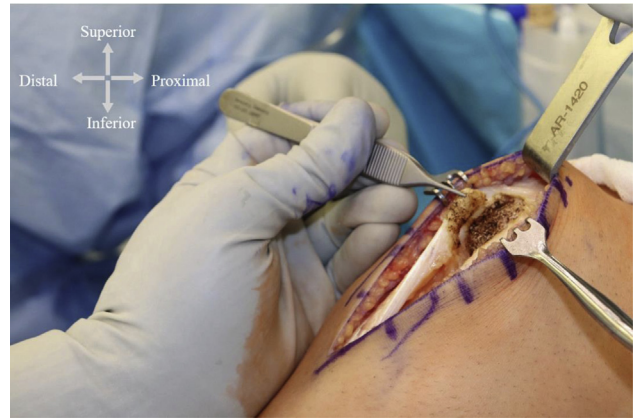### Tunnel Preparation

Before drilling tunnels, a thorough fat pad resection is performed to allow adequate visualization of the intercondylar notch. If necessary, a minimal notch-plasty may also be performed to open the distal femur through which the ACL graft will pass. An awl is used to mark the start point of the femoral tunnel, which is the anatomic footprint of the posterolateral bundle of the native anterior cruciate ligament.

The tibial footprint of the native ACL is used for accurate placement of the tibial tunnel. The tibial tunnel location is established with a standard tibial guide



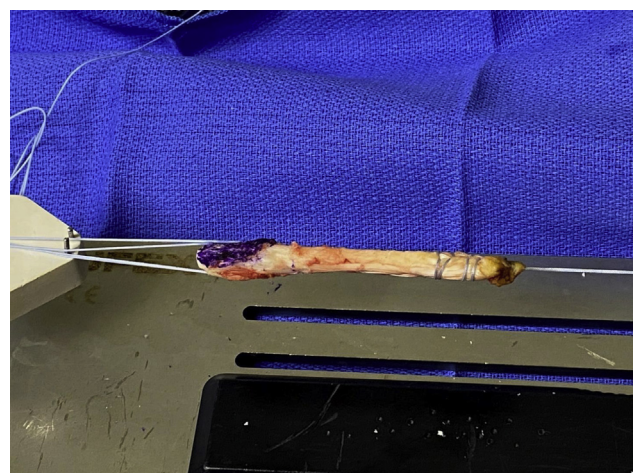
**Fig 2.** With the patient positioned supine, the knee is flexed to 90°. The paratenon is split and carefully reflected off of the underlying tendon. The middle third of the patellar tendon is used with a typical width of 10 to 11 mm. A full-thickness longitudinal incision of the patellar tendon is made from the inferior pole of the patella to the tibial tubercle. The medial aspect of the knee is located on the left of the figure with the lateral knee of the right of the figure. The head of the patient is at the top of the figure.



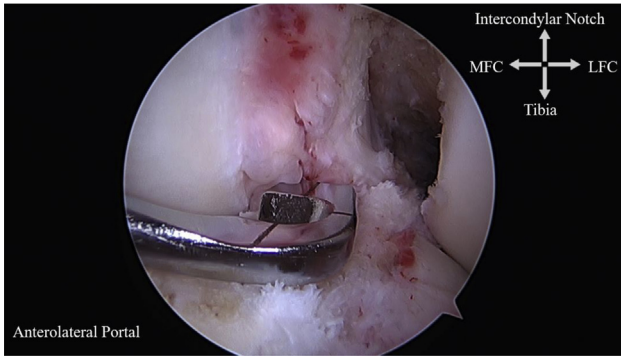
**Fig 3.** With the patient positioned supine, the knee is flexed to 90°. At the inferior pole of the patella, electrocautery is used to harvest the tendon. Electrocautery is used to elevate the tendon off of the patella in a subperiosteal fashion. Typically, an additional 5 to 10 mm of tendon can be obtained from the inferior pole. The proximal aspect of the patella is located on the right of the figure. Retractors are located within the medial and lateral skin flaps of the incision. The foot is at the left of the figure.

(Fig 5). After the guide pin has been placed in the accurate location and confirmed, the tibial tunnel is drilled (Fig 6). The size of the tibial tunnel is typically the same size as the femoral bone plug.

The knee is now brought up to a flexed position and a Beath pin placed through the medial portal into the start point previously marked with an awl. It is wise to drive the Beath pin into the medial wall of the lateral femoral condyle a few millimeters before knee hyperflexion to maintain the predetermined start point (Fig 7). The

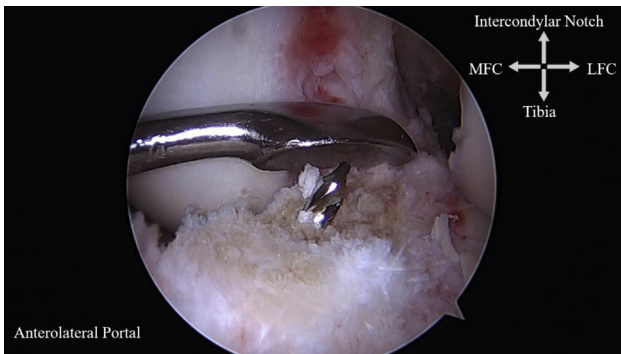


**Fig 4.** The tendinous end of the bone-tendon-autograft is prepared with a locking No. 2 FiberWire looped suture passed through the tendon. The bone plug is secured by passing a No. 2 FiberWire is then passed through 2 2.0-mm the drill holes. The cancellous portion of the bone plug is colored purple and the graft is placed on 15 to 20 pounds of tension.

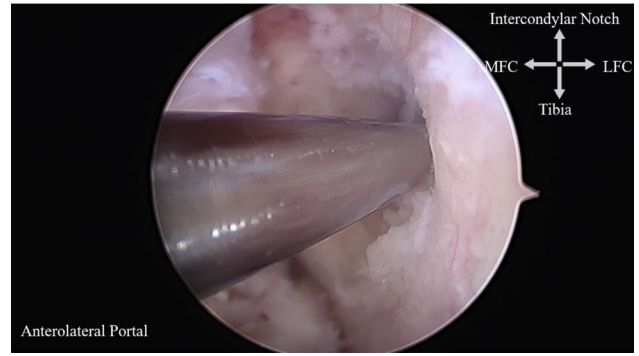


**Fig 5.** Viewing from the anterolateral portal, the tibial footprint of the native anterior cruciate ligament is used for accurate placement of the tibial tunnel. The tibial tunnel location is established with a standard tibial guide. On the right of the figure is the LFC; the MFC is on the left of the screen and the anterior aspect of the tibia is at the inferior portion of the figure. (LFC, lateral femoral condyle; MFC, medial femoral condyle.)

knee is then hyperflexed and the Beath pin advanced through the lateral femoral condyle. Hyperflexion allows for appropriate femoral tunnel placement in both the coronal and sagittal plane. The Beath pin is advanced until the tip punctures the lateral thigh skin. Once the tip of the Beath pin is out of the skin and appropriate tunnel placement is confirmed, an acorn reamer is used to drill the femoral tunnel approximately 25 mm in depth. After the femoral tunnel is created, a tunnel notcher is used to create a notch on the anterior aspect of the femoral tunnel to facilitate interference screw placement later. Next, a long PDS passing suture is placed through the eyelet of the Beath pin and the pin



**Fig 6.** Viewing from the anterolateral portal, after the guide pin has been placed in the accurate location and confirmed, the tibial tunnel is drilled. The guide pin position is verified using the remnant anterior cruciate ligament to ensure anatomic position of the tibial tunnel. On the right of the figure is the LFC; the MFC is on the left of the screen and the anterior aspect of the tibia is at the inferior portion of the figure. (LFC, lateral femoral condyle; MFC, medial femoral condyle.)

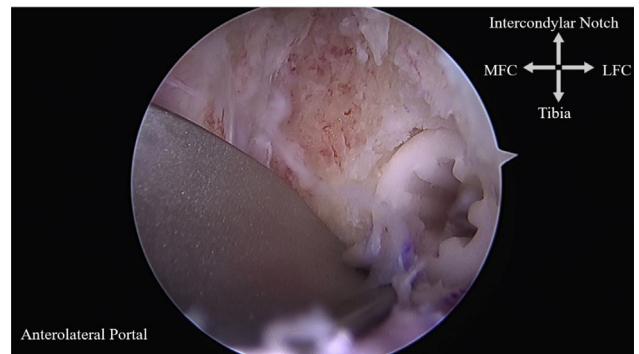


**Fig 7.** Viewing from the anterolateral portal, the knee is flexed to 90°, a Beath pin is placed through the medial portal into the femoral tunnel start point. On the right of the figure is the LFC; the MFC is on the left of the screen and the anterior aspect of the tibia is at the inferior portion of the figure. (LFC, lateral femoral condyle; MFC, medial femoral condyle.)

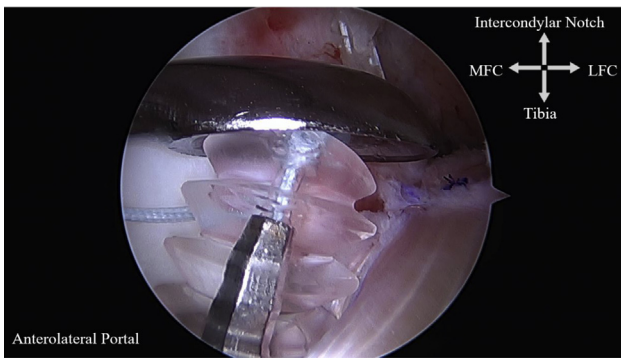
used to shuttle the free ends of the PDS suture out through the distal thigh.

### Graft Passage

The looped end of the shuttle suture is then retrieved through the tibial tunnel with a ring grasper. The bone-patellar tendon autograft is then removed from the tensioner and brought to the operative field. Both sutures from the tibial tubercle bone plug are passed through the tibial and femoral tunnels with the passing suture. To facilitate bone plug passage through the tibial tunnel and into the femoral tunnel, a probe inserted through the anteromedial portal can be used as a pulley to help guide the bone plug into the appropriate location. The cancellous portion of the graft is placed anterior in the femoral tunnel. Marking the cancellous portion with a marking pen during graft preparation makes the distinction between cancellous and cortical



**Fig 8.** Viewing from the anterolateral portal, the knee is hyperflexed for interference screw fixation. A biocomposite or metal interference screw is used for femoral fixation. The graft is protected using an arthroscopic sled. The interference screw on the right of the figure is inserted into the femoral tunnel. (LFC, lateral femoral condyle; MFC, medial femoral condyle.)



**Fig 9.** Viewing from the anterolateral portal, tension is maintained on the graft, and a large curette used to provide downward pressure; a RetroScrew is secured into the tibia obtaining interference fixation against the tendinous portion of the graft. The screwdriver within the RetroScrew is inserted anterior to the BTA graft through the tibial tunnel. On the right of the figure is the BTA exiting the lateral femoral condyle. The anterior aspect of the tibia is at the inferior aspect of the figure. (BTA, bone-tendon-autograft; LFC, lateral femoral condyle; MFC, medial femoral condyle.)

bone easier. Once the graft is in the appropriate position in the femoral tunnel, a nitinol wire is placed adjacent to the graft within the anterior aspect of the tunnel where the tunnel was previously notched. A 7 mm × 20 mm biocomposite or metal interference screw (at the preference of the surgeon) is then inserted to obtain femoral fixation (Fig 8).

For tibial fixation, we prefer the use of a tibial screw inserted antegrade from within the joint (RetroScrew, Tibial, Arthrex). Our preference for primary ACL reconstructions is for the circumference of the screw to be 1 size smaller than the tibial tunnel diameter (e.g., if a 9-mm tunnel was drilled, then an 8 mm × 20 mm screw would be used). A nitinol wire is passed through the tibial tunnel on the anterior aspect of the graft and then secured with a hemostat passed through the medial arthroscopic portal. Next, the cannulated RetroScrew driver is inserted over the nitinol wire. The nitinol wire is then removed and the stiff end of a FiberStick suture is passed through the screwdriver and into the knee joint (FiberStick, Arthrex). The suture is retrieved out of the knee joint through the anteromedial portal with the hemostat and passed through the RetroScrew, ensuring the tapered end of the screw is inserted first on the suture. A Mulberry knot is tied in the suture to prevent the RetroScrew from falling off of the suture. The RetroScrew is advanced through the anteromedial portal into the knee joint and inserted onto the screwdriver while visualizing arthroscopically. This step is facilitated by positioning the screw with the hemostat into a vertical position under the roof of the intercondylar notch. The end of the screw driver is advanced to fully engage the screw and is clearly visualized through the bioabsorbable RetroScrew.

While tension is maintained on the graft and a large curette used to provide downward pressure, the RetroScrew is secured into the tibia obtaining interference fixation against the tendinous portion of the graft (Fig 9). For added fixation on the tibial side, we pass the free ends of the sutures from the tendinous portion of the graft into a SwiveLock (BioComposite SwiveLock C, 4.75 mm × 19.1 mm, Arthrex), which is then inserted into the tibia just inferior to the tibial tunnel aperture (Video 1).

## Discussion

In conclusion, the BTA is a reliable, efficient, and reproducible technique for ACL reconstruction. The harvest of the graft is exactly the same as a standard BTB technique, until the decision to forgo the use of the patellar bone plug. Preoperative MRI scan assessment should be used to ascertain patellar tendon length and thus feasibility of this technique. However, intraoperative tendon and construct length measurement can be safely used to confirm feasibility before commitment of this technique. The advantages of this technique include faster graft harvest and preparation. Obviating the patellar bone plug harvest should eliminate the risk of perioperative patellar fracture and theoretically will mitigate donor site morbidity and kneeling pain, 2 of the most commonly cited complications of the use of BTB autografts for ACL reconstruction.<sup>3-5,7</sup>

Graft-tunnel mismatch is common technical complication for the ACL surgeon, often resulting in plug recession or protrusion from the tibial tunnel leading to inadequate osseous fixation. An option to address graft-tunnel mismatch include increasing the length of the tibial tunnel by adjusting the angle at which the tunnel is drilled. However, this may lead to decreased graft obliquity and potential alterations in the biomechanical properties of the graft.<sup>8,9</sup> The BTA ACL reconstruction provides versatility that allows the ACL surgeon to make an intraoperative decision on whether to proceed with a BTA or BTB autograft reconstruction without the need for significant changes in instrumentation. The potential complications of graft-tunnel mismatch are therefore eliminated with the BTA graft.

**Table 1.** Advantages Versus Disadvantages of the Bone-Tendon-Autograft

Advantages	Disadvantages
Decreased donor site morbidity	Loss of patellar bone plug
Elimination of potential graft-tunnel mismatch	
Elimination of the risk of perioperative patella fracture	
Allows for an intraoperative decision on whether to proceed with a bone-tendon-autograft or a bone-tendon-bone graft	
Faster graft harvest and preparation	

**Table 2.** Pearls and Pitfalls of the BTA Anterior Cruciate Ligament Reconstruction

Pearls
<ul style="list-style-type: none"> <li>• Thoroughly evaluate the patellar tendon length preoperatively and have available instrumentation for both bone-tendon-autograft or bone-tendon-bone graft harvest and fixation</li> <li>• A thorough fat pad debridement is essential to assist with RetroScrew visualization and insertion</li> <li>• Place nitinol wire anterior to graft for appropriate interference fixation</li> <li>• A large curette is beneficial to control anterior position of the RetroScrew as well as providing directional force for the screw to prevent the screw from wrapping around the graft</li> <li>• DO NOT pull on the screwdriver because it will disengage from the screw</li> <li>• Maintain appropriate tension on the graft during RetroScrew insertion</li> </ul>
Pitfalls
<ul style="list-style-type: none"> <li>• Posterior position of the interference screw can lead to inadequate fixation</li> <li>• Disengagement of the RetroScrew from the screw driver can lead to inadequate fixation and intra-articular screw prominence</li> </ul>

Limitations of this technique include the absence of the patellar bone plug. A benefit of the BTB autograft is the osseous incorporation of the graft. By eliminating the patellar bone plug, we therefore eliminate a point of osseous fixation within the tibial tunnel. Risks of this technique include inadequate preoperative planning in determining the patellar tendon length. Each patient's MRI scan evaluation should include a preoperative measurement of the patellar length to ensure that proceeding with a BTA is feasible. A BTA graft that does not have enough tendon length can lead to inadequate graft fixation. The advantages and disadvantages of the technique are presented in [Table 1](#), and pearls and pitfalls are presented in [Table 2](#).

## References

1. Samuelsen BT, Webster KE, Johnson NR, Hewett TE, Krych AJ. Hamstring autograft versus patellar tendon autograft for ACL reconstruction: Is there a difference in graft failure rate? A meta-analysis of 47,613 patients. *Clin Orthop Relat Res* 2017;475:2459-2468.
2. Gifstad T, Foss OA, Engebretsen L, et al. Lower risk of revision with patellar tendon autografts compared with hamstring autografts: A registry study based on 45,998 primary ACL reconstructions in Scandinavia. *Am J Sports Med* 2014;42:2319-2328.
3. Kartus J, Movin T, Karlsson J. Donor-site morbidity and anterior knee problems after anterior cruciate ligament reconstruction using autografts. *Arthroscopy* 2001;17:971-980.
4. Stein DA, Hunt SA, Rosen JE, Sherman OH. The incidence and outcome of patella fractures after anterior cruciate ligament reconstruction. *Arthroscopy* 2002;18:578-583.
5. Busam ML, Provencher MT, Bach BR. Complications of anterior cruciate ligament reconstruction with bone-patellar tendon-bone constructs: Care and prevention. *Am J Sports Med* 2008;36:379-394.
6. Miller MD, Hinkin DT. The "N + 7 rule" for tibial tunnel placement in endoscopic anterior cruciate ligament reconstruction. *Arthroscopy* 1996;12:124-126.
7. Ciccotti MC, Secrist E, Tjoumakaris F, Ciccotti MG, Freedman KB. Anatomic anterior cruciate ligament reconstruction via independent tunnel drilling: A systematic review of randomized controlled trials comparing patellar tendon and hamstring autografts. *Arthroscopy* 2017;33:1062-1071.e5. <https://doi.org/10.1016/j.arthro.2017.01.033>.
8. Fowler BL, Distefano VJ. Tibial tunnel bone grafting: A new technique for dealing with graft-tunnel mismatch in endoscopic anterior cruciate ligament reconstruction. *Arthroscopy* 1998;14:224-228.
9. Mcallister DR, Bergfeld JA, Parker RD, Grooff PN, Valdevit AD. A comparison of preoperative imaging techniques for predicting patellar tendon graft length before cruciate ligament reconstruction. *Am J Sports Med* 2001;29:461-465.